



WWW.DENTALLEARNING.NET

VOLUME 1 | ISSUE 7

DENTAL LEARNING

A PEER-REVIEWED PUBLICATION

Knowledge for Clinical Practice



Narrow-diameter Implants:

A Minimally Invasive Solution for Overdenture Treatment

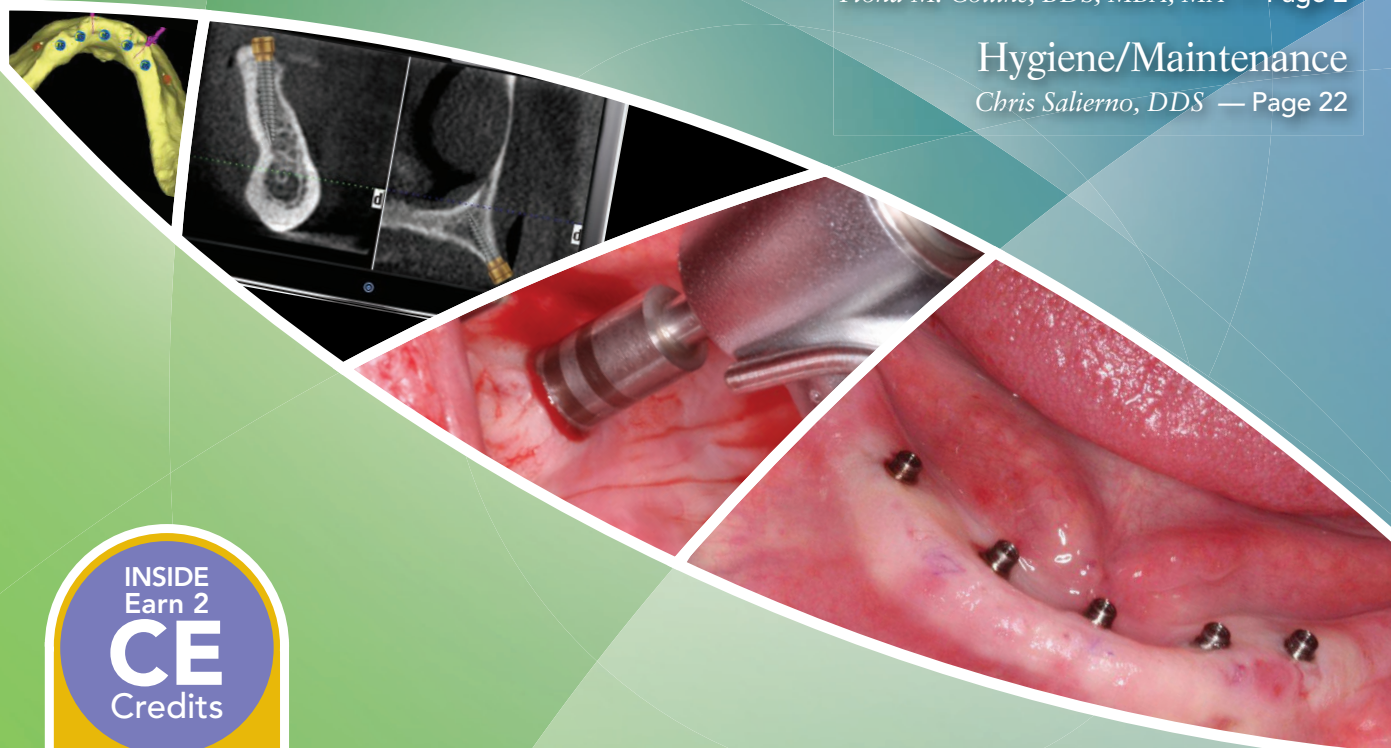
Paresh B. Patel, DDS

Foreword

Fiona M. Collins, BDS, MBA, MA — Page 2

Hygiene/Maintenance

Chris Salierno, DDS — Page 22



INSIDE
Earn 2
CE
Credits

Use coupon code
ZEST000DC7C7

A supplement to Dental Product Shopper



Foreword

Fiona M. Collins, BDS, MBA, MA

We are excited to provide you with the newest supplement in our series. This supplement contains a CE course on implant overdentures as well as a short article on patient home care and maintenance of implant overdentures.

The CE article, 'Narrow-diameter implants: A minimally invasive solution for overdenture treatment,' is written by Dr. Paresh Patel. The history of implant-retained overdentures, the potential patient benefits, rates of success and patient satisfaction are addressed in this article. This is followed by a focus on the use of narrow-diameter implants and attachments for patients where there may be less than optimal bone or anatomy.

At the conclusion of the article, the author presents cases demonstrating step-by-step procedures for the mandibular and maxillary arches.

We are also pleased to include a short article by Dr. Chris Salierno. This article reviews the home care requirements for oral hygiene as well as the overdenture itself. Additionally, an overview of the components of the periodic evaluation of implants and overdentures is provided, together with solutions for loss of retention or other issues that can occur with implant-retained overdentures.

We hope you will find these articles to be informative.

We would also like to thank you for your support of our supplements this year, and look forward to your suggestions for future articles as well as your continued interest next year.



Dr. Fiona M. Collins
CE Editor

Copyright 2012 by Dental Learning, LLC. No part of this publication may be reproduced or transmitted in any form without prewritten permission from the publisher.



DENTAL LEARNING

500 Craig Road, First Floor, Manalapan, NJ 07726

Editor
FIONA M. COLLINS

CE Content Manager
MONIQUE TONNESSEN

Creative Director
MICHAEL HUBERT

Art Director
MICHAEL MOLFETTO

Narrow-diameter Implants:

A Minimally Invasive Solution for Overdenture Treatment



ABOUT THE AUTHORS



Dr. Paresh B. Patel is a graduate of the University of North Carolina at Chapel Hill School of Dentistry and the Medical College of Georgia/American Academy of Implant Dentistry Maxi Course. He is the co-founder of the American Academy of Small Diameter Implants and is a clinical instructor at the Reconstructive Dentistry Institute with Dr. Ara Nazarian. He enjoys helping dentists incorporate implant dentistry as everyday dentistry into their practices. Dr. Patel has placed more than 3,500 small diameter implants and has lectured on this topic in the US, Brazil and Italy. He is also actively involved as a clinical consultant for several implant manufacturers, including ZEST Anchors, LLC, the sponsors of this course.

Dr. Patel can be reached at pareshpateldds2@gmail.com.

EDUCATIONAL OBJECTIVES

The overall goal of this article is to provide the reader with information on the treatment of edentulous patients with overdentures retained utilizing narrow-diameter implants and attachments. After reading this article, the reader will be able to:

1. List and describe considerations in overdenture treatment utilizing implants
2. Describe the concept behind myostatic denture design and how this can be achieved
3. Review the treatment planning for narrow-diameter implants
4. Review and describe the use of attachments with low vertical height

ABSTRACT

The use of implants in the edentulous arch has changed the way in which patients can be treated. Standard diameter implants have been utilized successfully for more than twenty years for overdenture patients, and more recently narrow-diameter implants have been utilized. Both standard and narrow-diameter implants have demonstrated high success and survival rates and are associated with improvements in function and patient comfort. Narrow-diameter implants offer the opportunity to provide implant-retained overdentures, without additional surgery, to patients who would otherwise require surgical procedures to augment bone prior to implant placement.

SPONSOR/PROVIDER: This is a Dental Learning, LLC continuing education activity. **COMMERCIAL SUPPORTER:** This course has been made possible through an unrestricted educational grant from ZEST Anchors, LLC. **DESIGNATION STATEMENTS:** Dental Learning, LLC is an ADA CERP recognized provider. ADA CERP is a service of the American Dental Association to assist dental professionals in identifying quality providers of continuing dental education. ADA CERP does not approve or endorse individual courses or instructors, nor does it imply acceptance of credit hours by boards of dentistry. Dental Learning, LLC designates this activity for 2 CE credits. Dental Learning, LLC is also designated as an Approved PACE Program Provider by the Academy of General Dentistry. The formal continuing education programs of this program provider are accepted by AGD for Fellowship, Mastership, and membership maintenance credit. Approval does not imply acceptance by a state or provincial board of dentistry or AGD endorsement. The current term of approval extends from 2/1/2012 - 1/31/2016. Provider ID: # 346890. Dental Learning, LLC is a Dental Board of California CE provider. The California Provider number is RP5062. This course meets the Dental Board of California's requirements for 2 units of continuing education. **EDUCATIONAL METHODS:** This course is a self-instructional journal and web activity. Information shared in this course is based on current information and evidence. **REGISTRATION:** This CE course is for 2 CE credits. **PUBLICATION DATE:** November, 2012. **EXPIRATION DATE:** October, 2015. **REQUIREMENTS FOR SUCCESSFUL COMPLETION:** To obtain 2 CE credits for this educational activity, review the material, complete the course evaluation and obtain a score of at least 70%. **AUTHENTICITY STATEMENT:** The images in this course have not been altered. **SCIENTIFIC INTEGRITY STATEMENT:** Information shared in this continuing education activity is developed from clinical research and represents the most current information available from evidence-based dentistry. **KNOWN BENEFITS AND LIMITATIONS:** Information in this continuing education activity is derived from data and information obtained from the reference section. **EDUCATIONAL DISCLAIMER:** Completing a single continuing education course does not provide enough information to result in the participant being an expert in the field related to the course topic. It is a combination of many educational courses and clinical experience that allows the participant to develop skills and expertise. **PROVIDER DISCLOSURE:** Dental Learning does not have a leadership position or a commercial interest in any products that are mentioned in this article. No manufacturer or third party has had any input into the development of course content. **CE PLANNER DISCLOSURE:** The planner of this course, Monique Tonnessen, does not have a leadership or commercial interest in any products or services discussed in this educational activity. She can be reached at mtonnessen@dentallearning.net. **TARGET AUDIENCE:** This course was written for dentists, dental hygienists, and assistants, from novice to skilled. **CANCELLATION/REFUND POLICY:** Any participant who is not 100% satisfied with this course can request a full refund by contacting Dental Learning, LLC, in writing. Go Green, Go Online to www.dentallearning.net take your course. Please direct all questions pertaining to Dental Learning, LLC or the administration of this course to mtonnessen@dentallearning.net.



Introduction

A major challenge for today's dental practitioner is how to properly manage the totally edentulous patient. During the 1960s and 1970s, implants started to be placed to satisfy this need; however, success rates were initially relatively poor. The only alternative solution, and the most economical one, was to offer tissue-supported dentures. Even with the best denture design and fabrication possible, and in the presence of adequate support, retention and stability were often issues and sources of patient discomfort and dissatisfaction. With the development of the endosseous root-form implant, this changed. From the 1990s until the present, a favorable treatment option has been the overdenture with two standard diameter implants as proposed by the McGill consensus statement.¹

By augmenting conventional therapy (complete dentures) with implants, many complications can be reduced. The inability to chew certain foods, denture pain, lack of retention, nutritional deficiencies, collapse of vertical dimension and poor psychological status can be corrected. There are several differing philosophies when utilizing standard body implants, such as location, size, and prosthetic overdenture design. Techniques utilized in the mandibular arch include placing one standard diameter implant in each of the canine or lateral incisor areas. Treatment of the edentulous patient with two standard body implants is well-researched and will at a minimum reduce the movement of a conventional lower denture. Implants can also improve chewing efficiency, bite force and quality of life.^{2,3,4,5} Both maxillary and mandibular implant-retained overdentures have demonstrated high success and survival rates.^{6,7} Anatomically, endosseous standard diameter implants can help preserve the alveolar bone.⁸ For patients, the use of implants translates into better facial aesthetics, increased self-confidence and fewer denture sores. With more clinicians embracing overdenture therapy, prosthetic complications associated with complete denture treatment in edentulous patients should decrease. The standard body implant may fulfill the requirement for denture stabilization for many patients.

A standard body implant is approximately 3.75 mm in diameter. The fact that this size was designed as the standard

diameter may have had some connection to the average width of a tooth root. To follow the guidelines when placing an implant of approximately 4 mm in diameter, approximately 6 mm of bone width in the facial-lingual dimension is required.⁹ However, an edentulous patient may lack sufficient alveolar bone to encase a standard diameter implant with the required 1 mm of bone circumferentially.¹⁰ The bone could be expanded with the use of osteotomes, however there still would not be 1 mm of native bone across the buccal aspect. Alternatively, it would be necessary to perform additional, more-invasive procedures such as a sinus lift or bone augmentation prior to placement of standard diameter implants. With acceptance, a different opportunity is to provide patients with overdentures retained by narrow-diameter implants that satisfy the anatomical/surgical constraints of the patient.

Narrow-diameter Dental Implants

Narrow-diameter implants (NDIs) are root-form endosseous implants that are less than 3 mm in diameter. As such, they provide a suitable alternative for patients with inadequate bone width for standard diameter implants (Fig. 1).

NDIs were originally designed to stabilize an interim prosthesis while conventional implants osseointegrated. When it was time to remove the NDIs, clinicians found that they had osseointegrated in around 50% of NDIs placed. Subsequently, their design features (macro and micro),

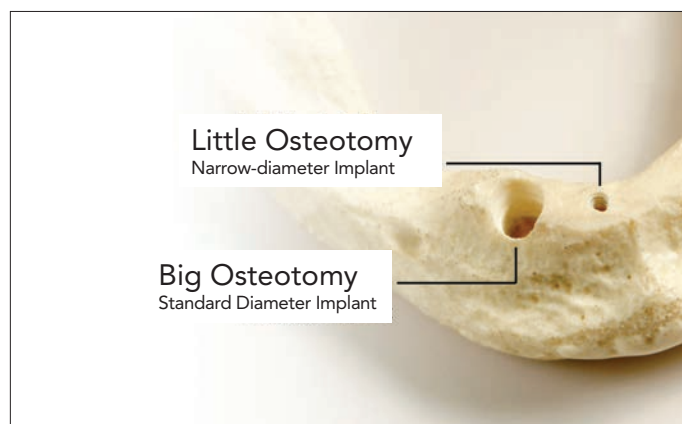


Figure 1. Comparison of osteotomy size with standard and narrow-diameter implants

Narrow-diameter Implants:

A Minimally Invasive Solution for Overdenture Treatment

insertion protocol and composition (stainless steel vs. titanium alloy) were changed. They are now typically made with the same Ti alloy and the same surface treatments as standard diameter implants. In 1997, NDIs were cleared by the FDA for “long-term intrabony applications.”¹¹

The macro design of most NDIs is a deep V pattern. This affords greater initial bone-to-implant contact (BIC), initial stability and a wider platform to dissipate occlusal forces. The micro design of NDIs now includes a rough surface to promote osseointegration. A study at Loma Linda University demonstrated this with a core sample of bone and implant 8 months after insertion with BIC similar to that of standard diameter implants.¹² The insertion protocol for NDIs has been simplified. Typically, one or two drills are used to make an undersized osteotomy and let the self-advancing, bone-condensing and compressing design of the implant draw itself into the dense bone. All these features in combination can allow the NDI to be immediately loaded in the edentulous mandible.¹³ However, osseointegration will not occur without stability, and a minimum of 30 Ncm of torque should be achieved before considering loading the implant.¹⁴ Since the body of the implant is narrow, this almost always ensures that it will be placed in good bone with two cortical plates for support and immediate immobility (Fig. 2). With a minimal amount of surgery, immediate circulation of blood and all the necessary healing factors occur quickly. This one-stage surgery with narrow-diameter implants is becoming more accepted.

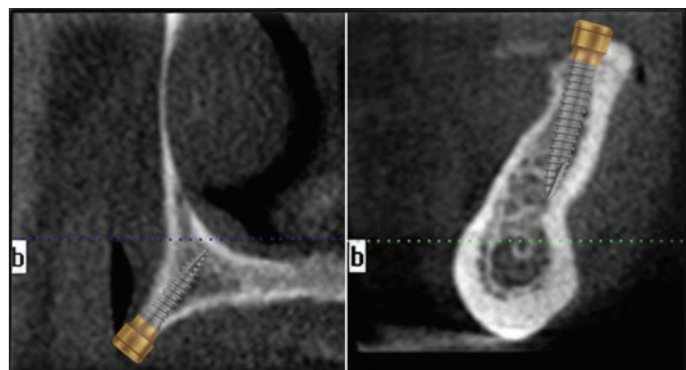


Figure 2. Narrow-diameter implants superimposed in areas with narrow bone

It has been estimated that 25% of patients who would benefit from implants do not do so due to inadequate bone, financial constraints, time constraints or compromised physical conditions.¹⁵ NDIs by design are minimally invasive, particularly when compared with alternative treatments such as bone augmentation or sinus lifts prior to implant placement; they can be placed with a single-stage flapless surgery protocol; and they are less expensive than standard diameter implant treatment with overdentures.^{16,17,18} Over the past decade, several studies have shown promising survival rates for tissue-supported overdentures retained by NDIs. One study found a survival rate of 90%, while two separate studies found higher survival rates. In the first study of 5 years' duration, 2,514 NDIs were placed for fixed and removable prostheses (with similar numbers of each type of prosthesis). The overall survival rate was 94.1% with a mean follow-up period of 2.9 years.¹⁹ A later report on 5,640 NDIs placed in 1,260 patients over a 12-year period with a mean follow-up period of almost four years found a survival rate of 92.1%.²⁰ Results have also demonstrated increased retention, stability and patient comfort with NDI-retained overdentures.²¹ Removable partial dentures can also be retained with NDIs.²¹ By utilizing NDIs for removable prostheses, the need to prepare adjacent healthy tooth structure for a precision attachment is often unnecessary (Kennedy Class I or II). Distal extensions can be kept from rocking while anterior sections of missing teeth can be replaced with greater esthetic results by removing the facial clasps. (Kennedy Class IV).

Not only can the removable prosthesis be stable, well-retained and retained esthetically, the implant will also help preserve the residual alveolar bone. Without implants, the edentulous areas will continue to atrophy. NDIs have also been shown to be effective for fixed prostheses. A seven-year retrospective study by Vigolo et al. followed 165 patients where 192 NDIs were placed to support single-tooth and multiple-implant restorations that were either cement-retained or screw-retained prostheses. A survival rate of 95.3% was reported.²² In recent years, NDIs have also been successfully utilized during orthodontic treatment for temporary anchorage (Table 1).^{23,24}

The focus of the remainder of this article is on the tissue-



| Table 1. Uses for NDI |
|-----------------------------|
| Mandibular complete denture |
| Maxillary complete denture |
| Single tooth replacement |
| Mandibular partial denture |
| Maxillary partial denture |
| Multiple missing teeth |

supported, NDI-retained overdenture.

Myostatic Denture Design

The primary goal for placing NDIs is to provide *retention* for a well-constructed full denture. The denture must be planned and executed correctly for long-term stability, success, and, ultimately, increased quality of life and satisfaction for patients. It must be tissue-supported on myostatic landmarks and have bilateral stability when in occlusion and function. Denture stability is strongly influenced by the denture's occlusion, which must be designed to avoid movement and tilting of the dentures when the opposing arches are in contact.²⁵ If these goals are accomplished, four correctly placed NDIs in the mandible and six NDIs in the maxilla will provide retention and result in patient satisfaction. It has often been said that implant dentistry is a prosthetic discipline with a surgical component. With that as our guiding principle, we begin with records that respect the myostatic design.

Myostatic principles are used to identify the areas in the edentulous mouth that will not move when swallowing, opening, closing or speaking. If dentures are constructed to this extension, they will be stable;²⁶ if built past these areas, they will move (myodynamic). Dentures with overextensions past these anatomical landmarks will create sore areas, will float and will be dislodged during function. In the maxilla, the hard palate, alveolar ridges and tuberosity are myostatic. An impression that captures these areas with correct vestibular extension will be sufficient to create a stable denture (Fig. 3).²⁶ A stable maxillary denture should not be confused with a retentive one. Well-constructed maxillary dentures can still

have little to no retention. The only way to add retention in these situations is to place implants. The mandibular arch is the opposite. With several muscle attachments, any overextensions will cause lifting of the denture. A full-arch impression is taken and poured in dental stone for evaluation and identification of all the important anatomical landmarks.²⁷ If any of these landmarks are missing, one must retake the impression and capture those.

There are several steps to taking an accurate impression and then utilizing this for mandibular models and an accurate record for an edentulous patient:

- With a pencil, an elliptical line is drawn around the retromolar pad, which is fibrous connective tissue and provides stability for the distal extension of the denture (Fig. 4)
- On the lingual side of the cast, the mylohyoid ridge is

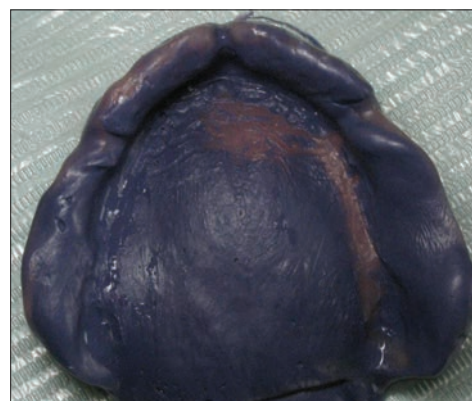


Figure 3. Upper impression

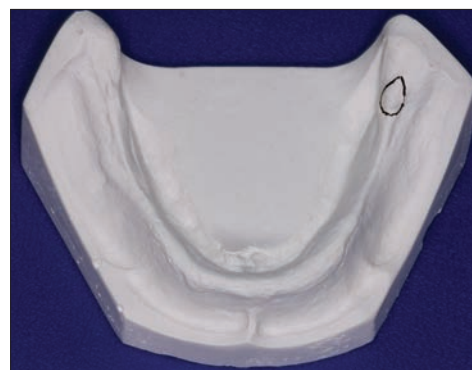

Figure 4. Mandibular model

Narrow-diameter Implants:

A Minimally Invasive Solution for Overdenture Treatment

then identified and marked. Any extension beyond this ridge will cause the denture to lift during function as the floor of the mouth rises (Fig. 5)

- Next, the external oblique ridge is identified on the facial side of the cast. This usually runs from second molar to second premolar. In the edentulous patient, the buccinator fibers detach as the alveolar bone resorbs and only remain attached to the mandible lateral to the external oblique ridge. If the denture base is kept even with the external oblique ridge, there is no possibility of the denture dislodging or creating sore areas as a result of the buccinator muscle contracting during function

- Easy landmarks such as the buccal and lingual frena are drawn in with a “V” mark. The mentalis is drawn in with oblong circles. With all the landmarks identified, the lines are connected. Particular care should be taken when connecting the retromolar pad to the external oblique ridge. The form should be a shallow curve to the anterior of the cast, to ensure that the denture base avoids the masseter muscle fibers (Fig. 6).

Once the locations of the extensions for the denture base are known, the only definitive way to transfer this information into the denture is to make a scribe line. Any team member can do this, from the assistant to the laboratory technician. A pointed instrument can be used and a line scribed 1 mm outside the line already drawn on the cast. If done in this manner, the laboratory technician can trim the

denture after processing. The extensions of the denture will be exactly to the pre-determined myostatic finish line. The denture will be extremely stable, have less potential for sore spots and offer good function.

Diagnosis and Treatment Planning

As stated earlier, overdenture therapy is a prosthetic discipline with a surgical component. When beginning a case, it is important to know where final tooth position, flange extensions and implants will be placed prior to placing implants. This can be achieved by creating a well-constructed mockup of the final denture in wax prior to implant placement. If the patient has a well-fitting denture, it can be duplicated very easily in one appointment with impression putty (Fig. 7). This duplicate denture can be used to help assess whether, if implants are placed in the key positions, there will be adequate room for the retentive housing and proper function and to allow for an esthetic result. Evaluating the available bone is easily performed with a panoramic radiograph and a set of study models. The radiograph aids assessment of how much vertical height of bone is available for the implants and aids treatment planning. The radiograph will not provide information on how much bone, and its volume, in the other three planes: anterior, posterior and lateral. This is where the study models and ridge mapping are critical. The volume of bone for implant placement can also be evaluated with 3-D cone beam CT. Prosthetic planning considerations

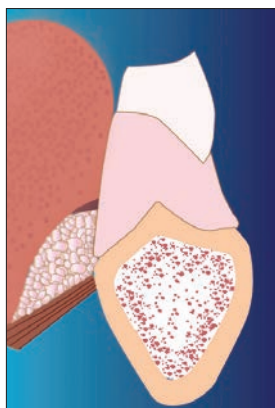


Figure 5. Anatomy of mylohyoid ridge region

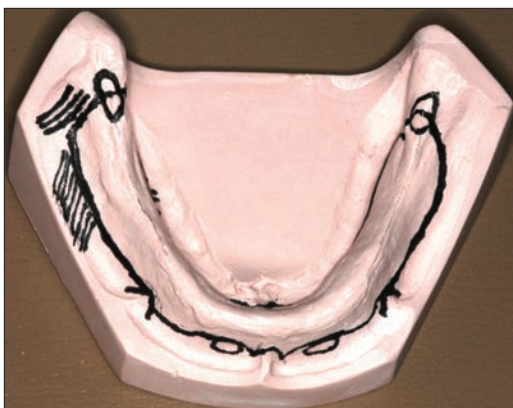

Figure 6. All anatomical landmarks connected on mandibular model

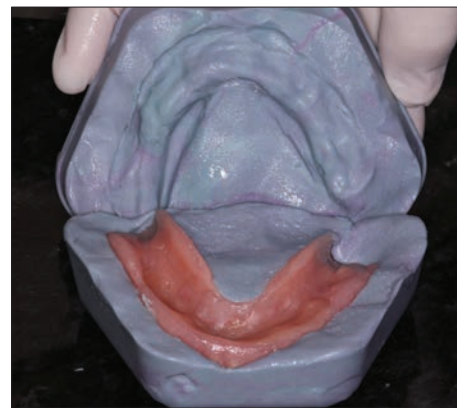

Figure 7. Denture duplication with putty



can be found in Table 2. The technique of ridge mapping is explained below.

Ridge Mapping

Four NDIs can be placed in positions between the mental foramina (A B D E positions) (Fig. 8). A fifth NDI can also be placed in position C if preferred. With the patient anesthetized and the key implant positions identified between the mental foramina, ridge mapping begins. Two measurements are made on the facial aspect, one on the crestal aspect and two on the lingual aspect of the residual alveolar ridge. This is performed using a periodontal probe to penetrate the soft tissue until bone is felt (Fig. 9). The assistant should record the depth on a chart that depicts the location and area. Once all four or five sites have been probed, the data is then transferred to the duplicated study model. The study model is then sectioned in the exact locations proposed for implant placement. A marker is used to transfer the depth marks to the model and the contour of the gingival tissue is colored in. Once this is completed, the exact dimensions of the residual ridge are known. By holding up the available sizes of NDIs, it can be determined which size will work best. Any issues with sloped bone can be identified and plans to flatten ridges can be made prior to surgery. The duplicate denture can also be placed over the cast to see if the proposed location and slope of bone will allow the NDIs to be contained within the

prosthesis. If any of these do not meet the clinical requirements, changes can readily be made.

Placement of the four NDIs 5 mm anterior to the mental foramina is ideal, to avoid impinging on any anterior loops of the nerve should these be present. That will usually place the distal implants in the premolar or canine region. The other two NDIs will be in the position where the lateral incisors would have been. If the residual ridge is wider and taller than normal, NDI placement behind the foramina can be an option to increase the anteroposterior (A/P) spread (the distance from the midline of the most anterior implant to the distal of the most posterior implants). If there are any frena or muscle attachments that would be impinged on by implant placement in ideal locations, these attachments should be released using a scalpel.

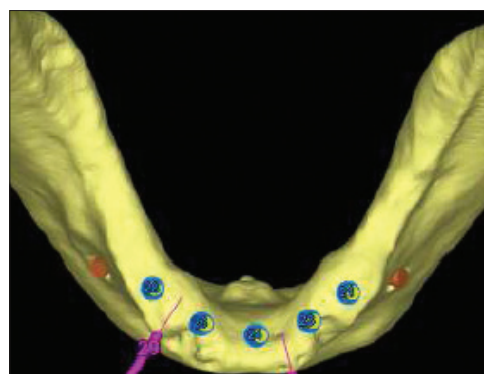


Figure 8. Key implant positions (A B C D E)

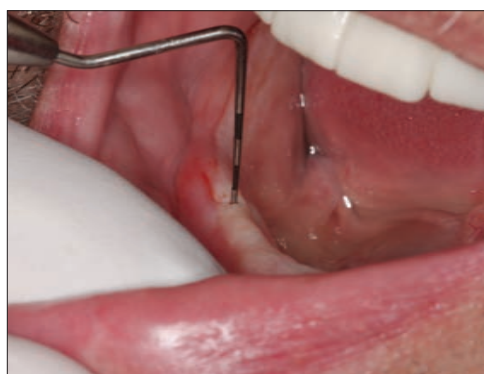

Figure 9. Periodontal probe to assess tissue thickness

| Table 2. Prosthetic planning considerations |
|--|
| Records |
| VDO with wax rims |
| Wax try-in |
| Esthetics |
| Phonetics |
| Jaw relationships |
| Occlusion |
| Bilateral stability |
| Inter-arch restorative space for the NDI and housing |

Narrow-diameter Implants:

A Minimally Invasive Solution for Overdenture Treatment

Treatment options for maxillary NDI overdentures are different than they are for the mandible. This is primarily because of the biomechanical disadvantages of the maxilla. One treatment option is to utilize six NDIs with a wide A/P spread. In the atrophic maxilla, NDIs will help maintain the residual ridge and are a less expensive treatment option than a fixed prosthesis. Based on the poor success rates reported in the literature and the greater potential for poor bone quality in the maxilla, immediate loading should not be considered without 30 Ncm of placement torque and a full palatal coverage overdenture. If 30 Ncm of placement torque is not achieved, the clinician must consider soft lining the overdenture or replacing the fixture with a larger-diameter implant. While implant number and location are more important than implant size, the use of as large an NDI as possible for the case is encouraged to maximize the implant surface area available for osseointegration and to maximize the potential for bicortical stabilization. The key implant positions in the maxilla should be second premolar, canine and lateral. The final NDI overdenture should have the same design features as a complete denture – full flanges and a palate that extends back to the tuberosity.

Avoiding Failure with NDIs

Failure with NDIs can be minimized with good treatment planning and consideration of anatomical factors and the number of implants required, as well as by following a precise protocol for the surgical and restorative phases of treatment. Factors to consider include the following:

Soft Tissue Thickness: If the tissue is greater than 2 mm, then consider reducing the tissue height to reduce the lever arm. A long lever arm will create stress on the NDI and can lead to failure.

Parallel Implants: All implants should be placed with great attention to alignment. If greater than 15-20 degrees of divergence is present (system dependent), failure can occur from increased off-axis forces. Patients also report greater difficulty in overdenture placement and removal.

Type of Bone: NDI will fare better in dense bone with little trabeculation. Ridge mapping will help determine the

facial-lingual width of bone. NDIs also have better results in Type I and II bone. Use caution in Type III and Type IV bone.

Number of NDIs: In the mandible four implants should be used, and in the maxilla six implants should be used to support an overdenture. The ratio is around two NDIs for every one standard diameter implant that would have been used.

Length of NDIs: No less than 10 mm should be used. The longest length possible should be considered to help increase surface area and provide initial stability.

Early Loading and Occlusion: Most NDIs are immediately loaded. Without 30 Ncm of placement torque, the immediate use of the implant should be questioned and a soft reline should be considered to allow opportunity for osseointegration.

Identification of Critical Anatomy in the Atrophied Mandible

After tooth loss, alveolar bone immediately begins to resorb.^{28,29,30} This is a result of missing impulses from the periodontal tissues into alveolar bone as well as systemic and metabolic factors. After the first year of tooth loss, more than 4 mm in height and 30% in crestal bone width is usually lost. Vertical loss will then continue at a rate of 0.1 mm to 0.5 mm per year.³¹ When placing NDIs in the resorbed mandible (Fig. 10), many areas of anatomy are of significant importance. Panoramic and lateral-view radiographs are

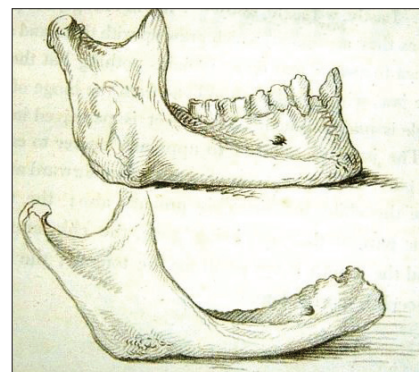


Figure 10. Mandibular resorption

Source: Bells 1806



necessary to identify the mental foramen and the shape, size and trajectory of the remaining bone. If access to a lateral cephalograph is not possible, a large No. 4 size film can be used. Alternatively, a CT scan can be utilized.

Mental Foramen: There are several ways to locate the mental foramen. One quick way is to draw an imaginary line from the patient's pupils straight down to the mandible. This gives a general idea of where the inferior alveolar nerve will exit. Another method is to place radiopaque material (e.g., composite, foil or gutta percha) in the denture near the second premolar location. Then, once the panoramic radiograph has been taken with the denture in place, there will be a visible reference point in relation to the denture. The ball end of a ball burnisher can also be used to "feel" the drop into the foramen; however, this is the most variable of the three techniques.

Lingual Artery and Submandibular Artery: One of the most important things to understand when placing implants is how mandibular bone resorbs. It is a down-and-out pattern toward the chin. Most general dentists are accustomed to the facial flare of the lower incisors. In the edentulous jaw, the pattern is opposite, with the superior crest of bone more lingual and the inferior cortical bone more facial. To avoid penetrating through the lingual plate with the cutting tip of the implant, one must be aware of this trajectory pattern. Us-

ing bone calipers or ridge mapping is necessary. An improper angle when placing NDIs with flapless surgery may lead to gross surgical complications. These complications include penetration of the lingual plate and perforation of the lingual or submandibular artery with potentially life-threatening hemorrhage in the floor of the mouth (Fig. 11).

Overdenture Attachments

Advantages of Attachments with Low Vertical Height

A large array of attachment devices is available for implant-retained overdentures, including O-ring balls, Locator attachments and ERA attachments. Due to the one-piece design of most NDIs, these are typically utilized unsplinted for overdentures and designed with an O-ball attachment. This attachment has proven to be effective in most situations.³² Another option now is the use of NDIs with a self-aligning attachment with low vertical height (the Locator attachment) that is also in use for standard diameter implants. Distinct advantages of this attachment are its ability to compensate for off-angle implants (without using angled abutments), useful in cases where there would have been insufficient vertical space for an O-ball (Fig. 12), and the variable retention that can be provided with these Locator attachments. Implants may diverge up to 20 degrees for up to a total of 40 degrees with two implants and still

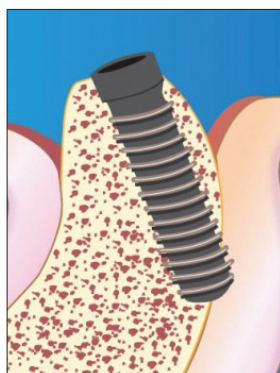


Figure 11. Incorrect positioning of the osteotomy bur results in lingual plate perforation

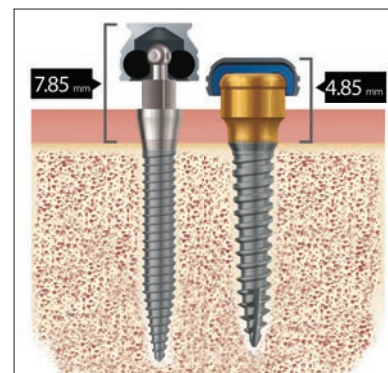
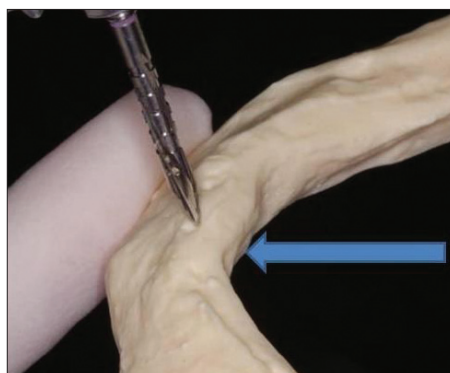


Figure 12. Height difference between O-ball and attachments with low vertical height

Narrow-diameter Implants:

A Minimally Invasive Solution for Overdenture Treatment



be able to be restored. In cases where the vertical height or interocclusal space is a challenge, the typical solution with O-ball attachments was to overcontour the denture to accommodate the bulky housing. This, however, leads to minimal tongue space and can create functional and speech difficulties. The retentive force placed on the implant can be varied chairside by selecting retentive inserts that are available from zero up to five pounds of force. It is recommended to use the insert with the least amount of force that will provide enough retention to have a satisfied patient. This will provide the required retention yet enable easier removal of the overdenture by the patient than would an insert with a higher retentive force.

The case studies below show the use of narrow-diameter implants with Locator attachments.

CASE STUDIES

Case 1: Flapless surgical technique for NDI placement in the mandible

A 55-year-old man presented with no lower teeth and an ill-fitting lower prosthesis (Figs. 13-14). His chief complaints were an inability to chew, pain on biting, and lack of confidence in social situations because his dentures would come out of his mouth. A comprehensive examination was performed. No signs of oral cancer were found,

and all soft tissues were deemed to be healthy, with sufficient keratinized tissue present to support a new overdenture. The mandibular arch was atrophied but on visual inspection appeared to have sufficient width and height to accommodate NDIs. A digital panoramic radiograph, clinical images and impressions for study models were taken, as well as ridge mapping measurements. Prior to the consultation appointment, the diagnostic data from the ridge mapping was used to draw in the width of available bone on the sectioned study cast. It was determined that four NDIs (2.9 mm diameter) could be placed between the mental foramina and in locations that would provide a minimum of 1 mm of bone circumferentially to encase the implant.

Surgical Procedure

The surgical sites were anesthetized with one carpule of 2% lidocaine with 1:100,000 epinephrine. A surgical marking pencil was then used to mark the four locations for the NDIs, based on the sectioned study models. A sharp endodontic explorer was next used to create bleeding points as well as to check for proper anesthesia. A 1.2 mm pilot drill was used to create the initial osteotomy and to assess the density of the cortical plate and trabecular bone. All four surgical sites were found to have

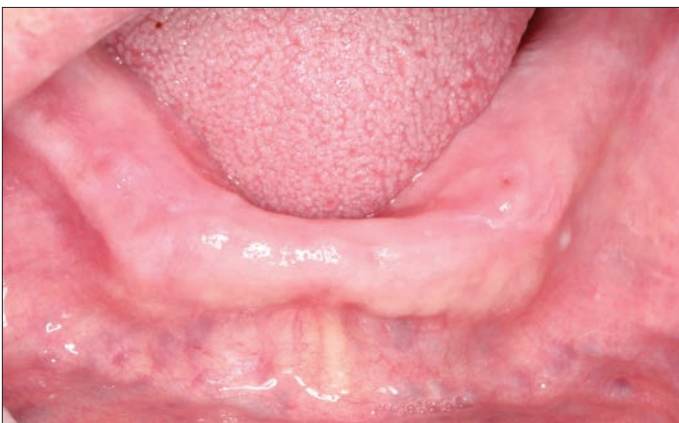

Figure 13. Edentulous mandibular arch

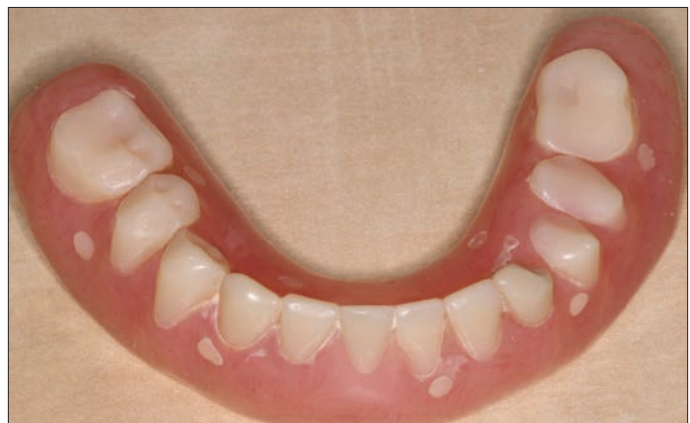

Figure 14. Poorly-designed and ill-fitting denture

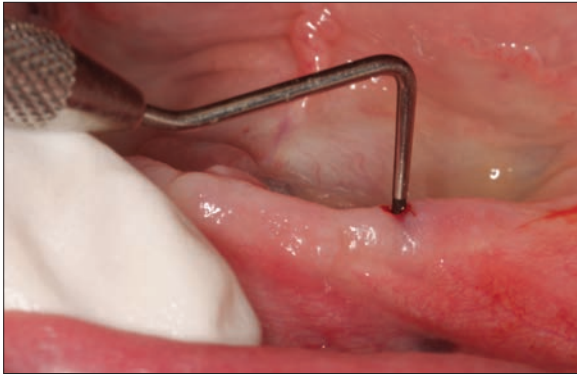


Figure 15. Using the blunt end of the endodontic explorer

dense bone (D1), thus the 1.2 mm pilot drill was carried to full depth. The blunt end of the endodontic explorer was then used to check that there were no perforations of the buccal or lingual plates (none were found) (Fig. 15). A rotary tissue punch was used to remove a perfect circle of gingiva (Fig. 16), which allowed for visualization of the bone and proper placement of the NDI collar and prevented epithelial tissue from entering the osteotomy. A final 2.4 mm drill was used to finish the osteotomy. A parallel pin was then placed at the site and the process repeated for the three remaining sites (Fig. 17). Once all osteotomies had been created, the NDIs were removed one by one from their sterile vials and inserted

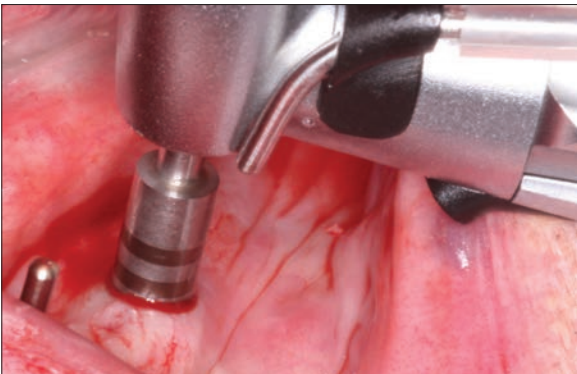

Figure 16. Using the rotary tissue punch

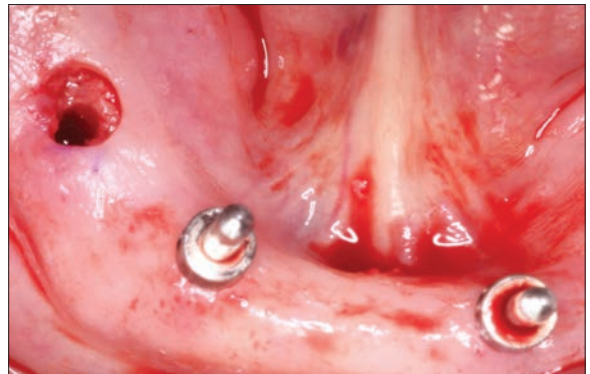


Figure 17. Visualization of bone for proper NDI placement and use of parallel pins

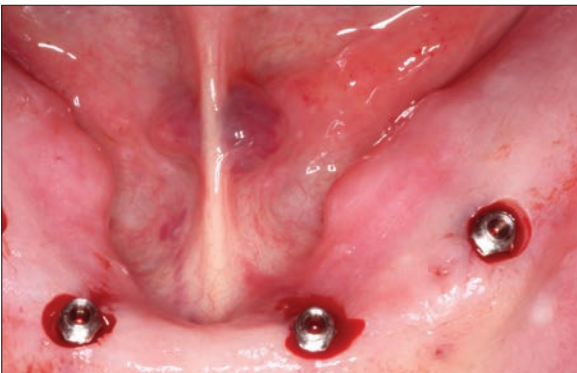


Figure 18. All NDIs in position

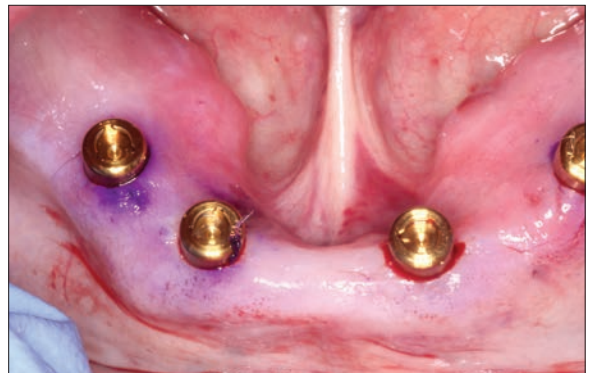

Figure 19. Attachments placed

Narrow-diameter Implants:

A Minimally Invasive Solution for Overdenture Treatment

into the osteotomy sites to 90% of full seating depth, using a handpiece driver. A torque wrench was then used applying up to 40 Ncm of torque to finish placement and primary stability was assessed (Fig. 18). The Locator attachments were then placed over the NDIs and torqued to 30 Ncm (Fig. 19). In this clinical case, because of the poor fit of the existing prosthesis, the retentive housings were not picked up chairside and instead this step was performed in the laboratory (had a well-fitting lower denture existed, the implants could have been loaded immediately). Impressions were then taken for the fabrication of a new lower overdenture, and a final panoramic radiograph was taken (Figs. 20-21).

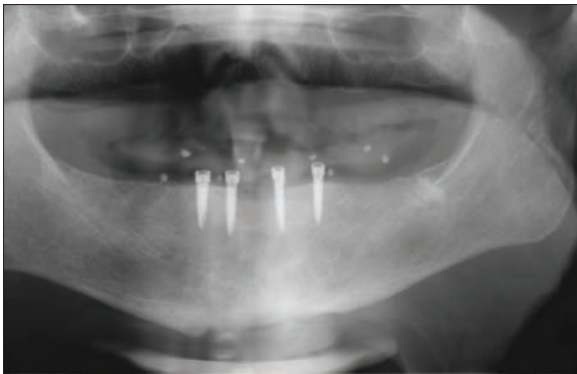


Figure 20. Final panoramic radiograph

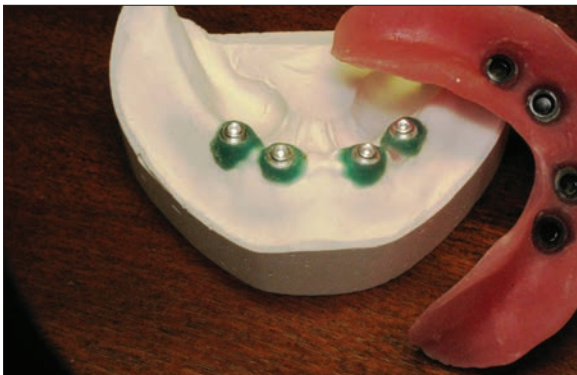

Figure 21. Model with block-out wax around the analogs and housings incorporated into the denture

Case 2: Flapless surgical technique for NDI placement in the mandible

A 64-year-old male presented with no lower teeth. The teeth had been extracted three years earlier, and he had recently lost his lower denture at the hospital. He had an existing upper overdenture supported with six Locator attachments. His chief complaint was that before he lost his denture, he noticed that it was getting more and more difficult to eat and that his denture was less retentive than when he first had it made. His upper denture was well-fabricated, and to improve his current situation a new lower overdenture would be made. After complete diagnostic records were collected, it was decided to obtain a cone beam CT scan because of the irregular ridge pattern. The cross sectional slices demonstrated that he would not be a good candidate for traditional-sized implants without additional surgery (Fig. 22). The anatomy of his residual lower ridge was an hourglass shape that would get thinner in the buccal-lingual dimension if the ridge was reduced. For this reason, 2.4 mm narrow-diameter implants with Locator attachments were selected. With the 2.4 mm NDIs, both the buccal and lingual plates would rigidly support the implant, avoiding the need for bone grafting or ridge splitting.

Five sites were selected in the symphysis area and were

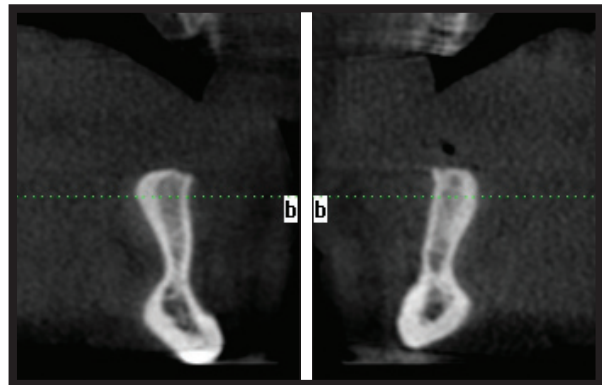


Figure 22. Cross-sectional slices showing narrow bone width

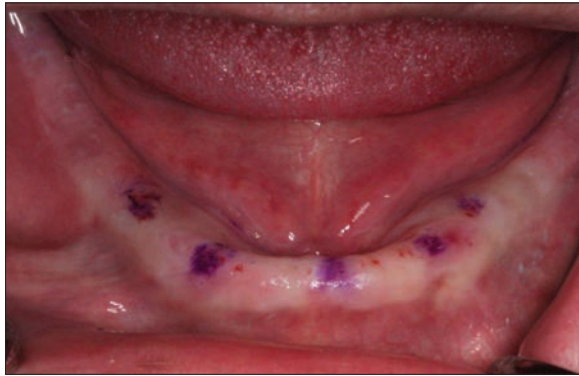


Figure 23. Implant sites marked




Figure 24. NDI attached to handpiece for placement

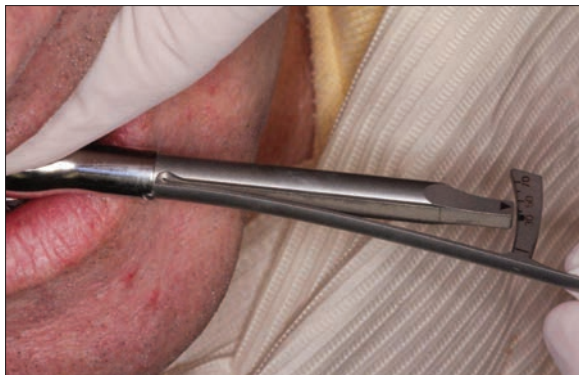

Figure 25. Torquing implant to 30 Ncm

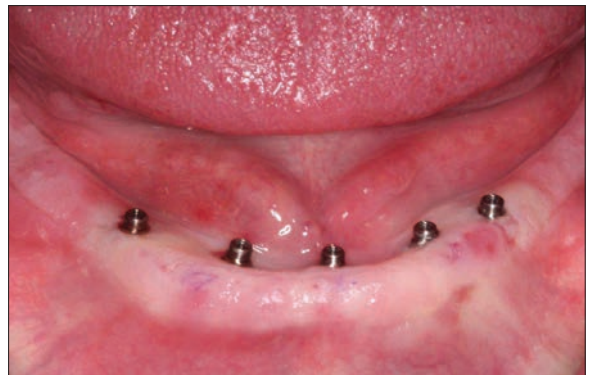

Figure 26. All five NDIs in place




Figure 27. Attachment on driver

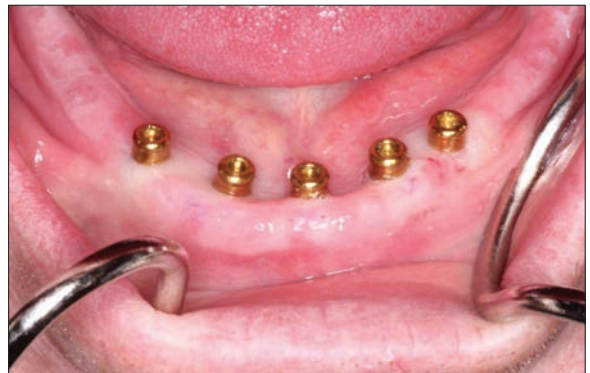

Figure 28. Attachments in position

Narrow-diameter Implants:

A Minimally Invasive Solution for Overdenture Treatment



Figure 29. Retentive males, white spacer and housing with processing male

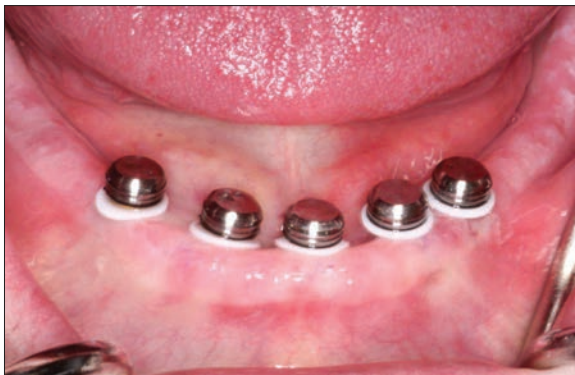

Figure 30. Housings with processing males in position, blockout spacer

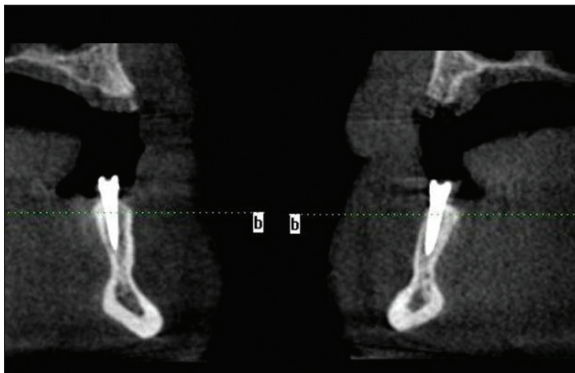


Figure 31. Post-placement CBCT images

marked with a surgical marking pencil (Fig. 23).

The necessary 1.2 mm pilot osteotomies were made and carried to full depth of the NDI selected, because of the dense nature of the bone encountered. Next, the osteotomies were prepared to full depth with the 1.6 mm drill. The implants were carried to the surgical sites and placed with the implant handpiece (Fig. 24). The implants were then fully seated with the torque wrench to ensure all threads were in bone (Figs. 25-26). One at a time, the included Locator attachments were removed from the top section of the sterile containers and hand-placed over the implant and then torqued to 30 Ncm to ensure an intimate connection (Figs. 27-28).

Over 45 Ncm of torque was obtained on the implant, thus immediate loading of the implants was possible. Along with the NDI, the packaging includes a male processing pack. The pack comes with the housing, three different retentive males and a white block-out spacer for chairside pickup (Fig. 29). If the patient had not lost his lower denture, the Locator housings could be placed and a retrofit with chairside pickup inside the denture could have occurred (Fig. 30). A post-implant placement cone beam CT was taken, and all five implants were found to be well-placed within the thin residual alveolar ridges (Fig. 31). The patient was thrilled with the outcome and was impressed that the NDIs were placed without making a surgical flap. He was also excited that his new lower overdenture could be started the day of implant placement and that the lower implants “felt” the same to him as his upper Locator overdenture.

Case 3: Flapless placement of NDIs for a maxillary overdenture

A 54-year-old male presented with full upper and lower dentures. His lower denture had been stabilized with O-ball mini dental implants. His chief complaint was that his upper and lower dentures were not as retentive as he would like. Clinically, the lower arch had two mini implants and would need two more implants to increase retention as the O-ball style housings do not offer the ability to increase retentive inserts. The upper arch clinically showed a broad

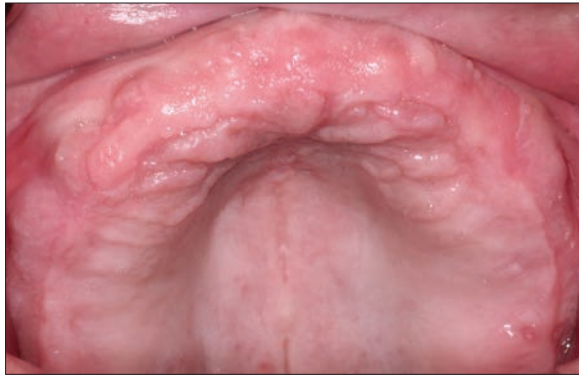

Figure 32. Pre-operative maxillary arch

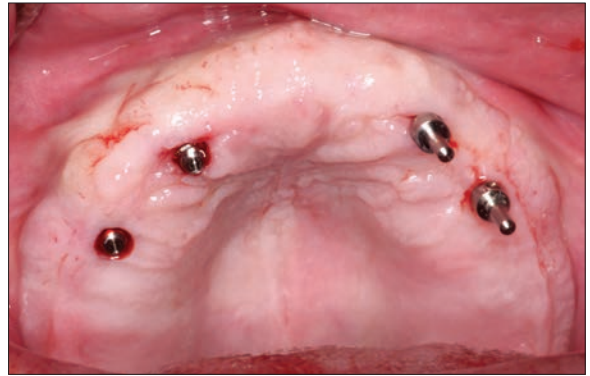


Figure 33. Two implants and parallel pins in position

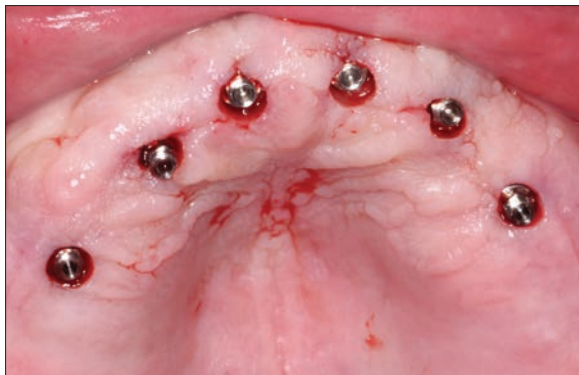

Figure 34. Additional implants placed in pairs for symmetry

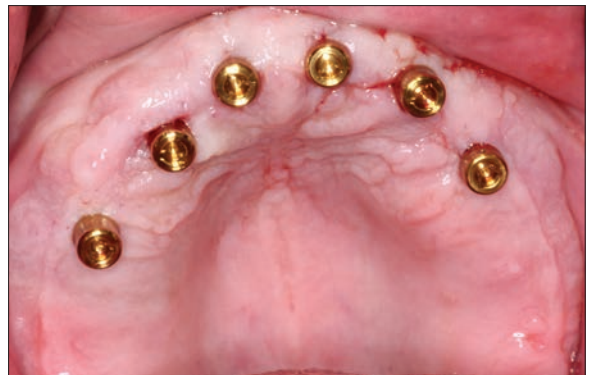

Figure 35. Attachments placed on implants

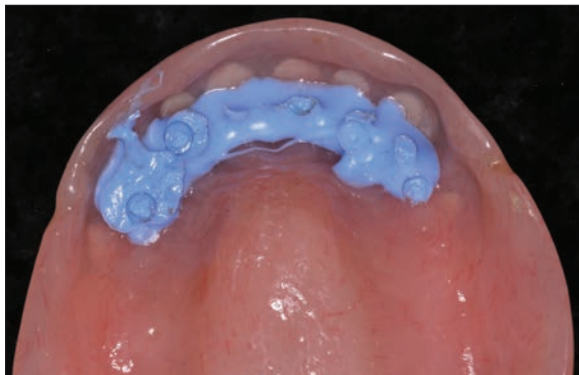

Figure 36. Checking the areas that will be relieved

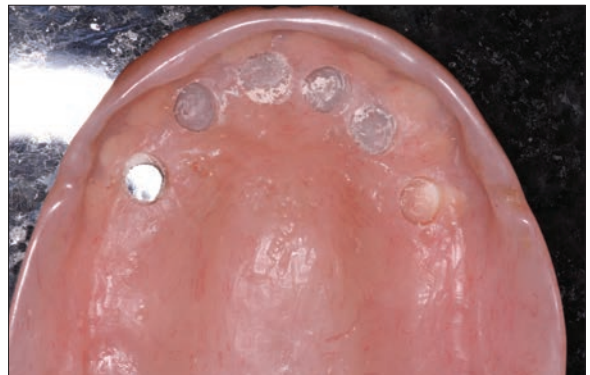

Figure 37. Post-reaming of the denture at the attachment sites

Narrow-diameter Implants:

A Minimally Invasive Solution for Overdenture Treatment

ridge, high palate vault and generally healthy mucosa (Fig. 32). In his medical history, he did disclose that he smoked around a pack of cigarettes per day. Diagnostic records were collected and a panoramic radiograph was taken. Radiographic analysis showed bilateral pneumatization of the sinuses. Because of his smoking history, sinus lifts and bone grafting were contraindicated, and it was decided to consider NDIs in the premaxilla. Ridge mapping measurements showed thick gingiva of around 4 mm and a thin ridge of around 3.7 mm in buccal-lingual width. Six sites were selected in the premaxilla as it is recommended to have more implants in the maxilla than in the mandible in order to support an overdenture.³⁹ The widest A/P spread was planned for with the most posterior NDIs being placed

first (Fig. 33). Additional implants were placed in pairs to ensure symmetrical distribution of load (Fig. 34). All implants placed were 2.9 mm in diameter. The implants were torqued to full depth, and more than 40 Ncm was obtained on all six implants enabling immediate loading of the implants. Guidelines for immediate loading can be found in Table 3. Locator attachments were then placed onto the implants (Fig. 35) and torqued to 30 Ncm. The block-out spacers were then placed gingivally around the implant-attachment complexes and the housings with processing males placed onto the attachments. Note that failure to use the block-out spacers would result in mixed acrylic flowing into undercuts around the attachment which would make removal of the denture impossible once the acrylic had set. The existing denture was filled in with quick-setting fit-check material to show where the denture would need to be relieved so that a passive fit could be ensured (Fig. 36). This process was repeated until no more acrylic showed through the material (Fig. 37). The relieved areas were then filled with mixed pick-up acrylic material and the denture seated over the housings until the acrylic set. The denture was then removed, any flash removed and the selected retentive males placed into the housings. A postoperative CT was taken. Although it appeared on the panoramic view that the two most posterior implants penetrated into the sinus cavity, CT slices showed that the implants were buccal to the area (Figs. 38-39).

Table 3. Guidelines for immediate loading of narrow-diameter implants in the mandible and maxilla

| |
|---|
| 5 mm facial/lingual width |
| 12 mm vertical height |
| Opposing a denture |
| Minimum of 4 implants between the mental foramina Minimum of 6 implants in the maxilla |
| Bi-cortical stabilization |
| Minimum of 10 mm of implant thread in bone |
| Absence of bruxism or other parafunctional habits |

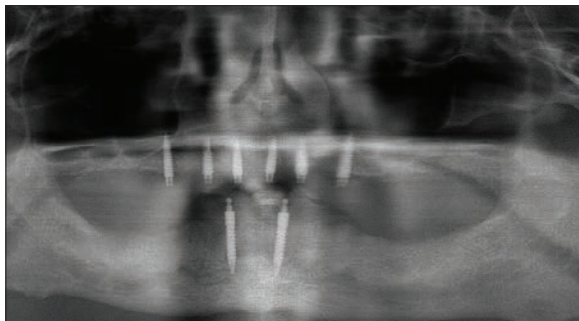


Figure 38a. Post-operative panoramic radiograph

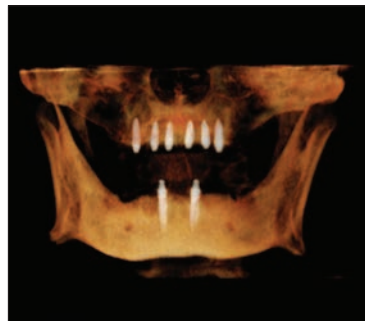


Figure 38b. Post-operative CT scan

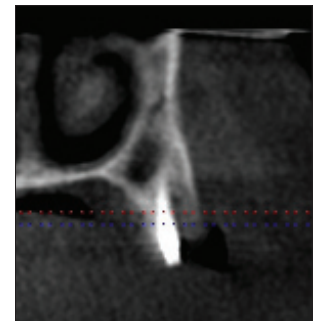


Figure 39. Post-operative CT slice showing implant buccal to the sinus



Conclusions

Narrow-diameter implants can be placed using a flapless approach and have micro and macro features that facilitate a simplified insertion protocol. Because of the NDIs' reduced diameter, cases with limited or resorbed bone can be treated with implant-retained overdentures where this would otherwise not be possible without performing procedures to augment bone. Thus, NDIs provide a minimally invasive technique for overdenture treatment that increases the retention and function of overdentures as well as patient comfort and satisfaction. NDIs are also available with self-locating attachments with low vertical height, that increase the flexibility in implant positioning and enable overdenture treatment in cases where inter-arch height is a factor, and also increase patient comfort. Implant-retained overdenture treatment improves patients' quality of life, and these newer treatment options increase the choices for patients with anatomical limitations and offer minimally invasive treatments.

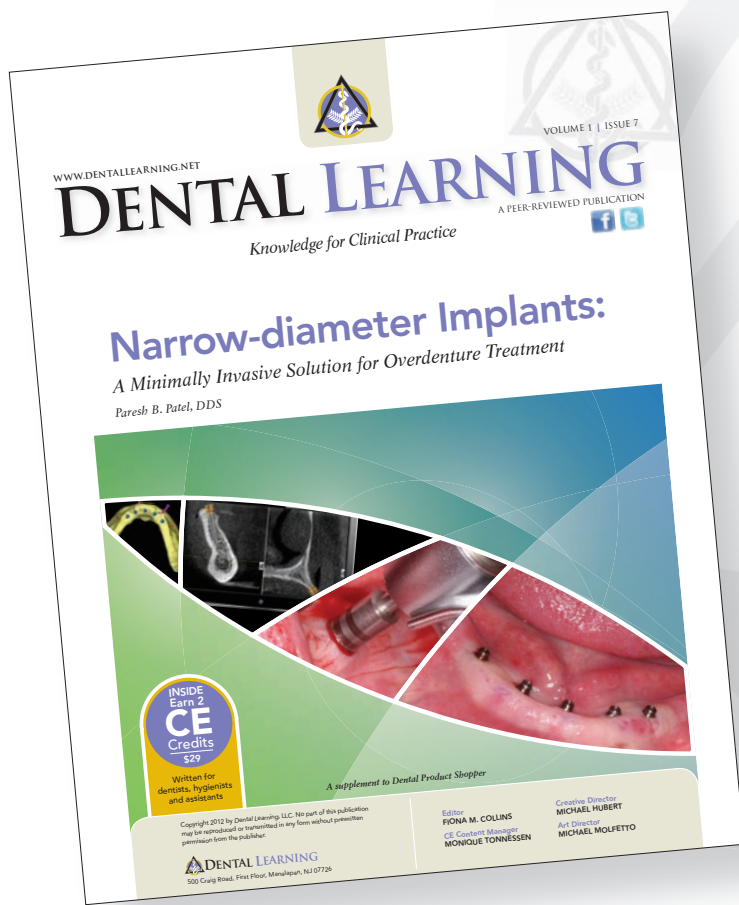References

1. Feine JS, Carlsson GE, Awad MA, et al. The McGill consensus statement on overdentures. *Int J Prosthodont*. 2002;15(4):413-414.
2. Awad MA, Lund JP, Dufresne E, Feine JS. Comparing the efficacy of mandibular implant retained overdentures and conventional dentures among middle-aged edentulous patients: satisfaction and functional assessment. *Int J Prosthodont*. 2003 Mar-Apr;16(2):117-122.
3. Thomason JM, Lund JP, Chehade A, Feine JS. Patient satisfaction with mandibular implant overdentures and conventional dentures 6 months after delivery. *Int J Prosthodont*. 2003;16(5):467-473.
4. Turkyilmaz I, Company AM, McGlumphy EA. Should edentulous patients be constrained to removable complete dentures? The use of dental implants to improve the quality of life for edentulous patients. *Gerodontology*. 2010 Mar;27(1):3-10.
5. Heydecke G, Locker D, Awad MA, Lund JP, Feine JS. Oral and general health-related quality of life with conventional and implant dentures. *Community Dent Oral Epidemiol*. 2003 Jun;31(3):161-168.
6. Slot W, et al. A systematic review of implant-supported maxillary overdentures after a mean observation period of at least 1 year. *J Clin Periodontol*. 2010;37(1):98-110.
7. Cooper LF, et al. Five-year prospective evaluation of mandibular overdentures retained by two microthreaded, TiOblast nonsplinted implants and retentive ball anchors. *Int J Oral Maxillofac Impl*. 2008;23(4):696-704.
8. Reddy MS, Geurs NC, Wang IC et al. Mandibular growth following implant restoration: Does Wolff's Law apply to residual ridge resorption? *Int J Perio Restor Dent*. 2002;22(4):
9. Flanagan D, Mascolo A. The mini dental implant in fixed and removable prosthetics: a review. *J Oral Implantol*. 2011 Mar;37 Spec No:123-132.
10. Misch CE. Contemporary implant dentistry. Mosby Elsevier. 3rd ed., 2008.
11. Christensen GJ. The 'mini'-implant has arrived. *J Am Dent Assoc*. 2006;137(3):387-390.
12. Li Y, Lee SS, Zhang W, Apresio R, Zunt SL. Tissue Responses to Two Mini Dental Implants in Miniature Swine. Abstract #351. AADR 2012, Tampa FL.

13. Lerner H. Minimal invasive implantology with small diameter implants. *Impl Pract*. 2009; 2(1):30-35.
14. Ahn MR, An KM, Choi JH et al. Immediate loading with mini dental implants in the fully edentulous mandible. *Impl Dent*. 2004;13(4):367-372.
15. Rossein KD. Narrow body implants preserve patients' quality of life. *Oral Health*. 2007; 39-50.
16. Christensen GJ. The increased use of narrow-diameter implants. *J Am Dent Assoc*. 2009;140(6):709-712.
17. Bulard RA, Vance JB. Multi-clinic evaluation using mini-dental implants for long-term denture stabilization: A preliminary biometric evaluation. *Compend Contin Educ Dent*. 2005;26(12):892-897.
18. Elsyad MA, Gebreel AA, Fouad MM, Elshoukoui AH. The clinical and radiographic outcome of immediately loaded mini implants supporting a mandibular overdenture. A 3-year prospective study. *J Oral Rehabil*. 2011;38(11):827-834.
19. Shatkin TE, Shatkin S, Oppenheimer BD, Oppenheimer AJ. Mini dental implants for long-term fixed and removable prosthetics: a retrospective analysis of 2514 implants placed over a five-year period. *Compend Contin Educ Dent*. 2007 Feb;28(2):92-99; quiz 100-101.
20. Shatkin TE, Petrotto CA. Mini dental implants: A retrospective analysis of 5640 implants placed over a 12-year period. *Compend Contin Educ Dent*. 2012;33(Spec Iss 3):1-7.
21. Griffiths TM, Collins CP, Collins PC. Mini dental implants: an adjunct for retention, stability, and comfort for the edentulous patient. *Oral Surg Oral Med Oral Pathol Oral Radiol Endod*. 2005;100(5):e81-4.
22. Vigolo P, Givani A, Majzoub Z, Cordoli G. Clinical evaluation of narrow-diameter implants in single-tooth and multiple-implant restorations: a 7-year retrospective study. *Int J Oral Maxillofac Impl*. 2004;19(5):703-709.
23. Yamaguchi M, Inami T, Ito K, Kasai K, Tanimoto Y. Mini-implants in the anchor-age armamentarium: new paradigms in the orthodontics. *Int J Biomater*. 2012;2012:394121. Epub 2012 Jun 5.
24. Reynders R, Ronchi L, Bipat S. Mini-implants in orthodontics: a systematic review of the literature. *Am J Orthod Dentofacial Orthop*. 2009;135(5):564.e1-19.
25. Davies SJ, Gray RM, McCord JF. Good occlusal practice in removable prosthodontics. *Brit Dent J*. 2001;191:491-502.
26. Moses CH. Physical considerations in impression making. *J Prosthet Dent*. 1953;3:449-463.
27. Carlsson GE. Facts and fallacies: an evidence base for complete dentures. *Dent Update*. 2006 Apr;33(3):134-6,138-40,142.
28. Christensen GJ. Ridge preservation: why not? *J Am Dent Assoc*. 1996 May;127(5):669-670.
29. Schmidlin PR, Jung RE, Schug J. Prevention of alveolar ridge resorption after tooth extraction – a review. *Schweiz Monatsschr Zahnmed*. 2004;114(4):328-336.
30. Winkler S. Implant site development and alveolar bone resorption patterns. *J Oral Implantol*. 2002;28(5):226-229.
31. Atwood DA, Coy WA. Clinical, cephalometric, and densitometric study of reduction of residual ridges. *J Prosthet Dent*. 1971 Sep;26(3):280-295.
32. Marzola R, et al. Immediate loading of two implants supporting a ball attachment-retained mandibular overdenture: a prospective clinical study. *Clin Implant Dent Relat Res*. 2007;9(3):136-143.

Webliography

- Allen F. Patients very satisfied with implant supported dentures. Evidence-Based Dentistry (2006) 7, 34. Available at: <http://www.nature.com/ebd/journal/v7/n2/full/6400397a.html>
- Esposito M, Grusovin MG, Achille H, et al. Interventions for replacing missing teeth: different times for loading dental implants. *Cochrane Database Syst Rev*. 2009 Jan 21;(1):CD003878. Abstract available at: <http://www.ncbi.nlm.nih.gov/pubmed/19160225>.
- Stanford S. Mini-screws success rates sufficient for orthodontic treatment. Evidence-Based Dentistry (2011) 12, 19. Available at: <http://www.nature.com/ebd/journal/v12/n1/full/6400777a.html>



Web-based CE Opportunity at www.dentallearning.net



- 1) Go to www.dentallearning.net
- 2) Click on the tab "**CE COURSES**" and choose the course titled:
Narrow-diameter Implants: A Minimally Invasive Solution for Overdenture Treatment.
- 3) Click on the button "**Take course**"
- 4) Login or Register to Complete Course
- 5) Read through course and at the bottom of the page click on "**Claim CE Credits**"
- 6) **Bypass Credit Card information and place your Rep Code (ZEST000DC7C7) in the Coupon Code Box then click "**APPLY TO ORDER**"**
- 7) Click on "**Review Order**" and it will bring your order up for review then click on "**Submit Order**"
- 8) Then input answers and click on "**Submit**"
- 9) Fill out the evaluation and click on "**Submit**"
- 10) You can immediately download your Verification of Completion or login at a later date and print off the Verification of Completion

Complimentary code
ZEST000DC7C7



Hygiene and Maintenance:

Protocols for Implant Overdentures

Chris Salierno, DDS

Introduction

Patients who have been rehabilitated with a complete denture retained by implants may incorrectly believe that they no longer require recall appointments. However, edentulous patients do require periodic evaluation to maintain peri-implant health and monitor the integrity of the removable prosthesis.

Evaluation of Implants

According to the American Academy of Periodontology, there are several considerations for a recall patient presenting with implants, including oral hygiene status, clinical appearance of peri-implant tissues, presence of bleeding on probing and/or exudates, probing depths, and radiographic bone levels.¹ In the case of an implant overdenture, the clinician begins with an interview of the patient regarding his or her home care.

Home Care

The patient's dentures should be soaked once a day,² then rinsed under water. A brush designed for dentures will help remove bulk debris. Preferably the patient will leave the prosthesis soaking to reduce the chances of developing conditions such as oral malodor, opportunistic fungal infections, and inflammatory papillary hyperplasia. The patient should also incorporate the cleaning of implant abutment surfaces into his or her home care regimen. Hygienic access to overdenture abutments is less complicated than access to fixed implant restorations, especially if the abutments for the overdenture are not splinted together. The peri-implant sulcus may be debrided by various methods including the use of soft toothbrushes, soft interdental brushes, floss of varying thickness, and oral irrigators. Any dentifrices used should be low-abrasive to avoid damaging the implant and abutment surfaces. This regimen should be repeated twice daily as with natural teeth. The discussion regarding home care is combined with an examination of plaque and calculus accumulation on the prosthesis and implant abutments to form a comprehensive picture of the patient's ability

to maintain his or her oral environment. Once the clinician has an understanding of the patient's hygienic abilities, the health of the peri-implant tissues is assessed. Peri-implant mucositis is diagnosed by the presence of bleeding on probing, while peri-implantitis is diagnosed by the pathologic loss of crestal bone.³ Plaque and calculus that reside on the abutment or in the peri-implant sulcus are removed by the clinician with the appropriate armamentarium. Hygiene instruments for mechanical debridement are typically made from plastic or graphite so as to avoid scratching the surfaces, which would aid bacterial colonization (Fig. 1).



Figure 1. Implant scalers

Evaluation of Prosthesis

The clinician assesses the retention of the prosthesis. Patients have different occlusal forces, dietary habits, and functional border movements; thus the evaluation of the retentive forces begins with the clinician asking the patient how effectively he or she is able to function in speech and mastication. If the patient desires increased retention, the dentist will check for worn-out or dislodged attachments. The most common complication encountered with implant overdentures is related to the matrix-patrix complex.⁴ The matrix is the receiving component that is typically housed in the denture, while theatrix is the engaging component that is typically fixed to the implant. The matrix-patrix system may fail as a result of the matrix becoming dislodged from the denture or theatrix from the implant, or due to wear or fracture of the matrix oratrix. Depending upon the attachment system that has been used, repair of these complications may be simple or more complex.

If a matrix-patrix attachment system is intact but the

Hygiene and Maintenance: *Protocols for Implant Overdentures*

patient notes poor retention, the clinician may suspect compromised tissue support. Although retention of an implant overdenture is primarily achieved by the attachment system, a lack of tissue support will overload the matrix-patrix complex. This may present as the prosthesis “rocking” in the anterior-posterior or medial-lateral dimensions. The clinician should consider a chair-side or laboratory reline of the denture if poor tissue support is suspected. If the overdenture exhibits good tissue support and a functional matrix-patrix complex, the problem may lie with inadequate retention force of the attachments.

Many manufacturers design matrix systems that may be replaced with identical components with the same retention as originally or that offer increased retention force. Patients have different preferences for retentive forces of their prosthesis, so there is an advantage to using a system that offers flexibility with attachment strength (Figs. 2-3).

The inspection of the prosthesis continues with any signs of occlusal wear of the denture teeth. The rate of wear depends on the patient’s masticatory forces, the presence of parafunctional habits, and the nature of the opposing dentition. If excessive wear is present the patient may exhibit a loss of occlusal vertical dimension. To restore loss of facial height in this situation, the denture teeth may be replaced by a laboratory. If the wear of the denture teeth appears to occur at a rapid rate, the patient should be evaluated for parafunctional habits and bruxism. The prosthesis should also be examined for the presence of fracture lines. These are more likely to appear in the area of the matrix-patrix complex due to the amount of space required for the implant abutment and attachment apparatus.⁵ If early signs of fracture are noted, a chair-side or laboratory reline may help prevent crack propagation. Use of attachment systems with a lower height will help prevent these fractures.

Finally, the prosthesis may be cleaned by mechanical and chemical means. Gross debridement using large denture brushes will remove bulk plaque and food debris. Subsequently, the prosthesis may be placed in a bag with ultrasonic solution designed to remove more tenacious calculus and stain. The bag is placed in an ultrasonic bath for the recommended amount of time for best results.

Conclusions

Patients with implant overdentures must be kept on an appropriate recall system. A successful rehabilitation is designed to be implant-retained and tissue-supported. For that success to be maintained, the surrounding tissues must remain free



Figure 2. A Locator core tool removed the black processing male

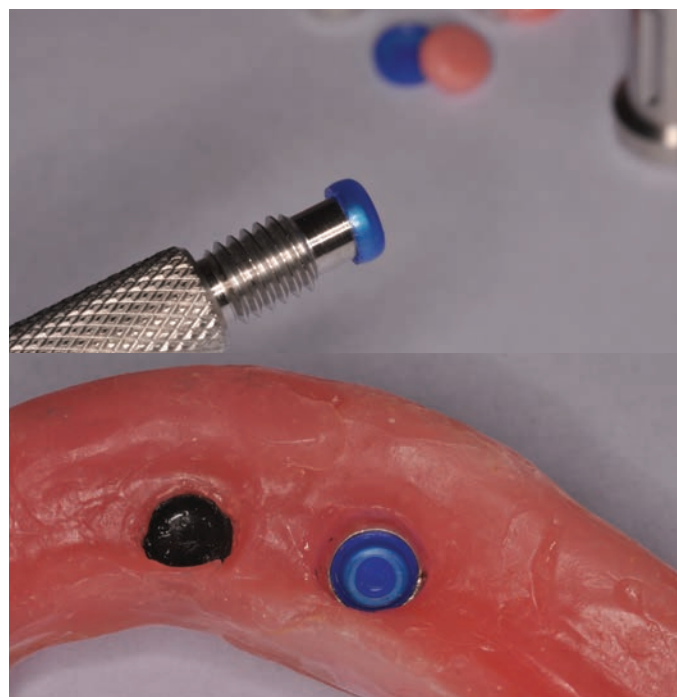


Figure 3 and 4. The same tool is used to place a blue male with 1.5 lbs. of retention force into the housing

from peri-implant disease and the prosthesis must function properly within the patient’s functional ability.

References

1. American Academy of Periodontology. Parameter on placement and management of the dental implant. *J Periodontol* 2000;71(suppl):870-872.
2. Zarb GA, Bolender CL, Carlsson GE. Boucher’s Prosthodontic Treatment for Edentulous Patients. 11th ed. Mosby, 1997, 379-380.
3. Academy of Osseointegration. 2010 guidelines of the academy of osseointegration for the provision of dental implants and associated patient care. *Int J Oral and Maxillofac Implants* 2010;25:620-627.
4. Payne AGT, Solomons YF. The prosthodontic maintenance requirements of mandibular mucosa- and implant-supported overdentures: A review of the literature. *Int J Prosthodont* 2000;13:238-245.
5. Allen PF, McMillan AS, Smith DG. Complications and maintenance requirements of implant-supported prostheses provided in a UK dental hospital. *Br Dent J* 1997;182:298-302.

IT'S TIME TO REPLACE THE O-RINGS AGAIN... WITH AN ENTIRELY NEW TECHNOLOGY.



Out with the old.



In with the new.



Introducing the new LOCATOR® Overdenture Implant System (LODI) featuring narrow diameter implants. Designed to work perfectly with our best-in-class LOCATOR Attachments, LODI offers the valuable attributes of narrow diameter implants, but with the flexibility of a unique two-piece coronal design not found with O-ball mini implants. It's this unique design that allows for the flexibility of attachment replacement should wear occur throughout time.

LOCATOR Overdenture Implants are constructed from the strongest titanium available and feature a proven RBM surface. The LODI system incorporates all of LOCATOR's sought-after features, including its patented, pivoting technology and customizable levels of retention, while also having a dramatically reduced vertical height compared to O-ball mini implants.

Say so long to O-Rings and hello to the LOCATOR Overdenture Implant System.
Available winter of 2012. For more information, call 1.855.868.LODI (5634)
or visit our new website at www.zestanchors.com/lodi/dps